University of Michigan
Medical School

Potential Role of Physiologic MR and PET Imaging in Management of Brain Metastases

Christina Tsien, M.D

University of Michigan

Role of Physiologic/Metabolic Imaging

- Optimal timing of drug delivery in combination with radiation
- Early treatment response prior to changes in anatomic MRI
- Early Imaging Biomarker of late CNS neurotoxicity

Dynamic Contrast Enhanced (DCE) MRI: To Assess Tumor Vascular Permeability

University of Michigan Medical School

Contrast-Enhancing Rim

Non-Enhancing Tumor Core

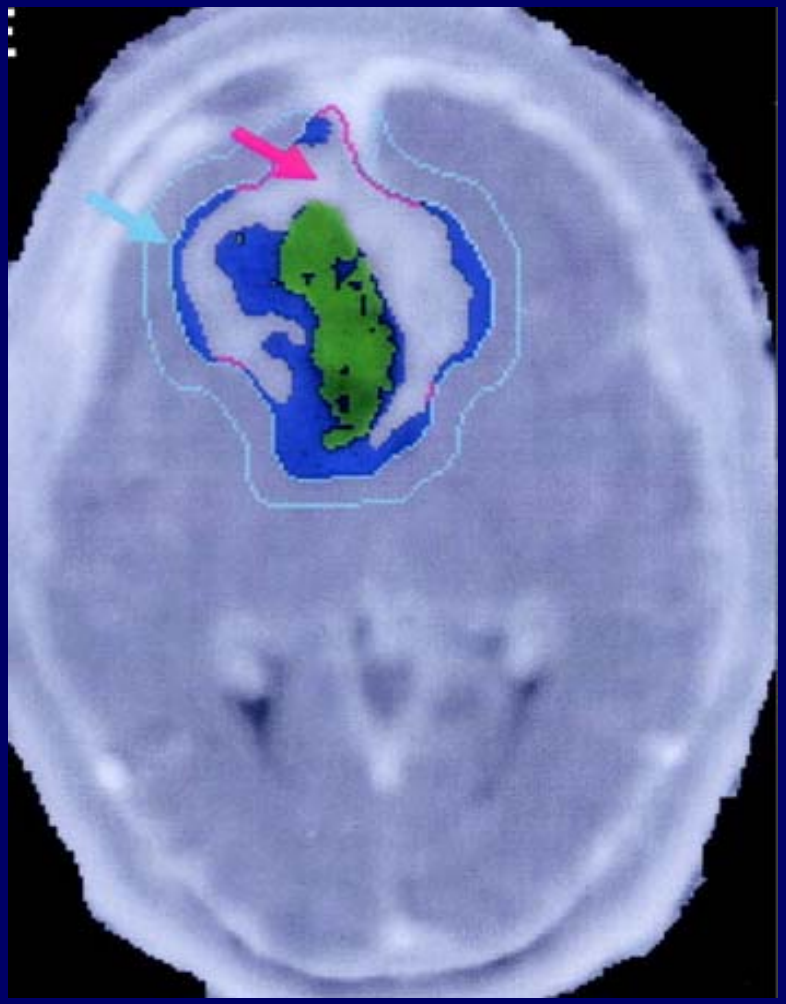

Optimal Timing for Drug Delivery?

Contrast Enhancing Rim

Non Enhancing Tumor Core

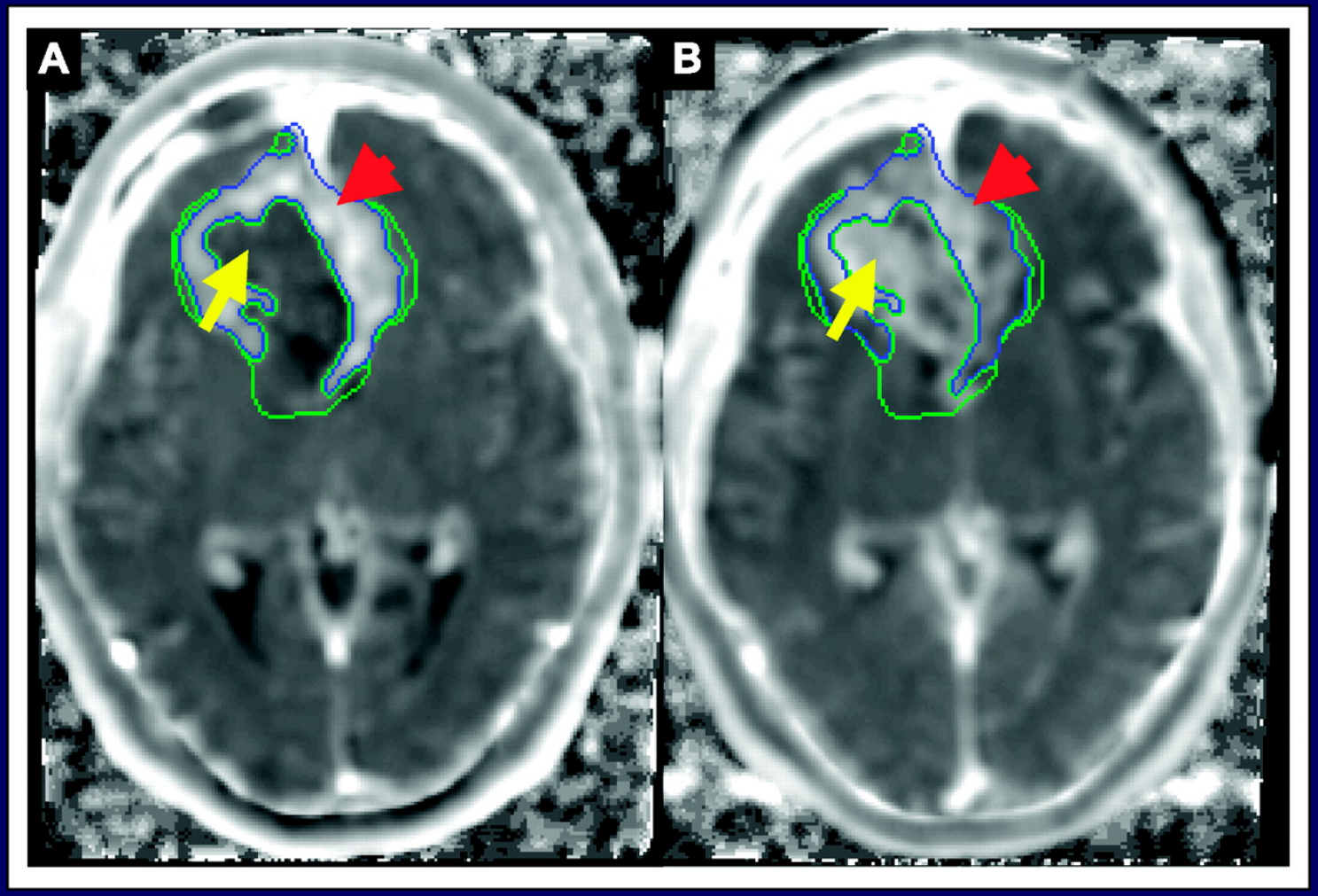

Pre-RT

Wk 3 during RT

Cao, Y. et al. J Clin Oncol; 24:1228-1235 2006

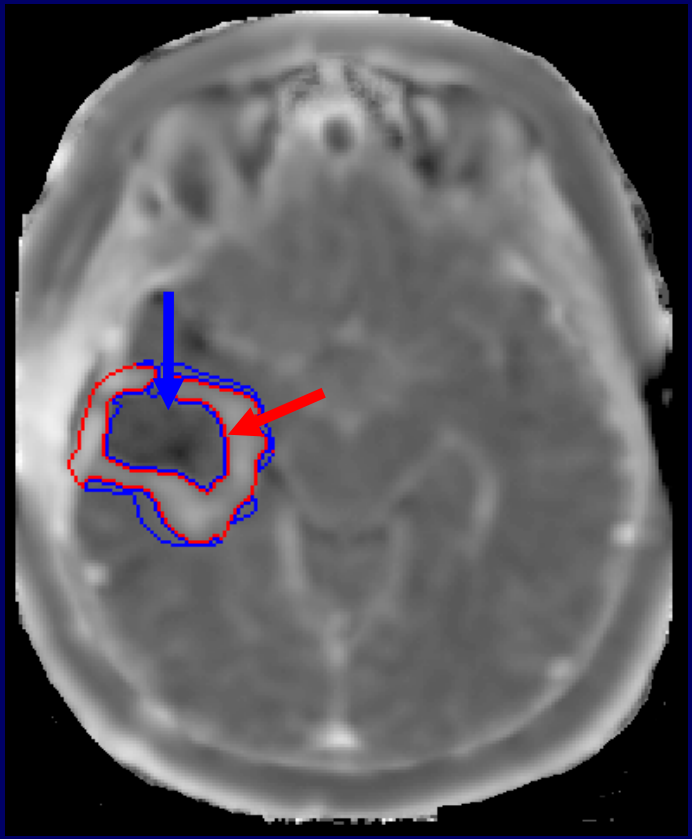

Pre-Tx

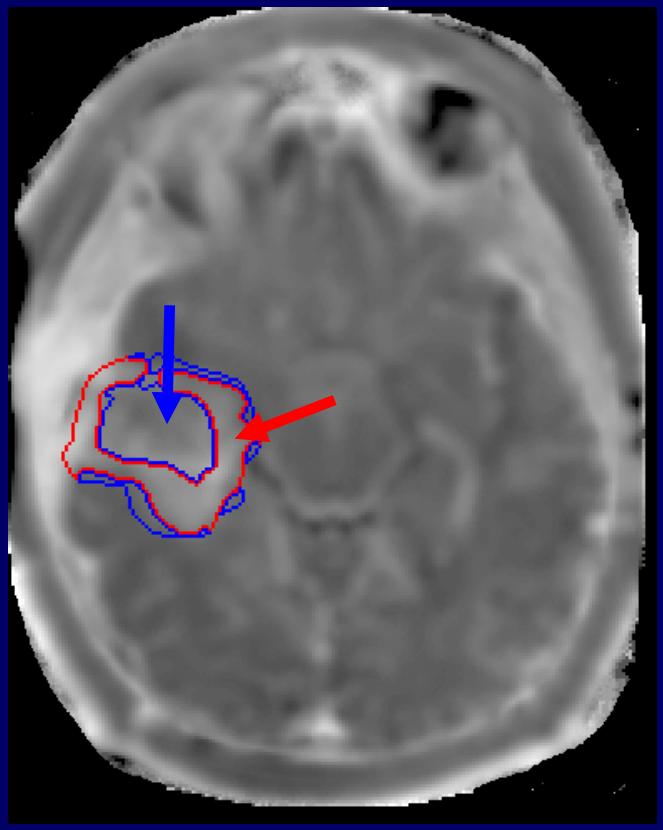

Wk 3 RT

Changes of the mean (Gd-DTPA) uptake indices during and following RT)

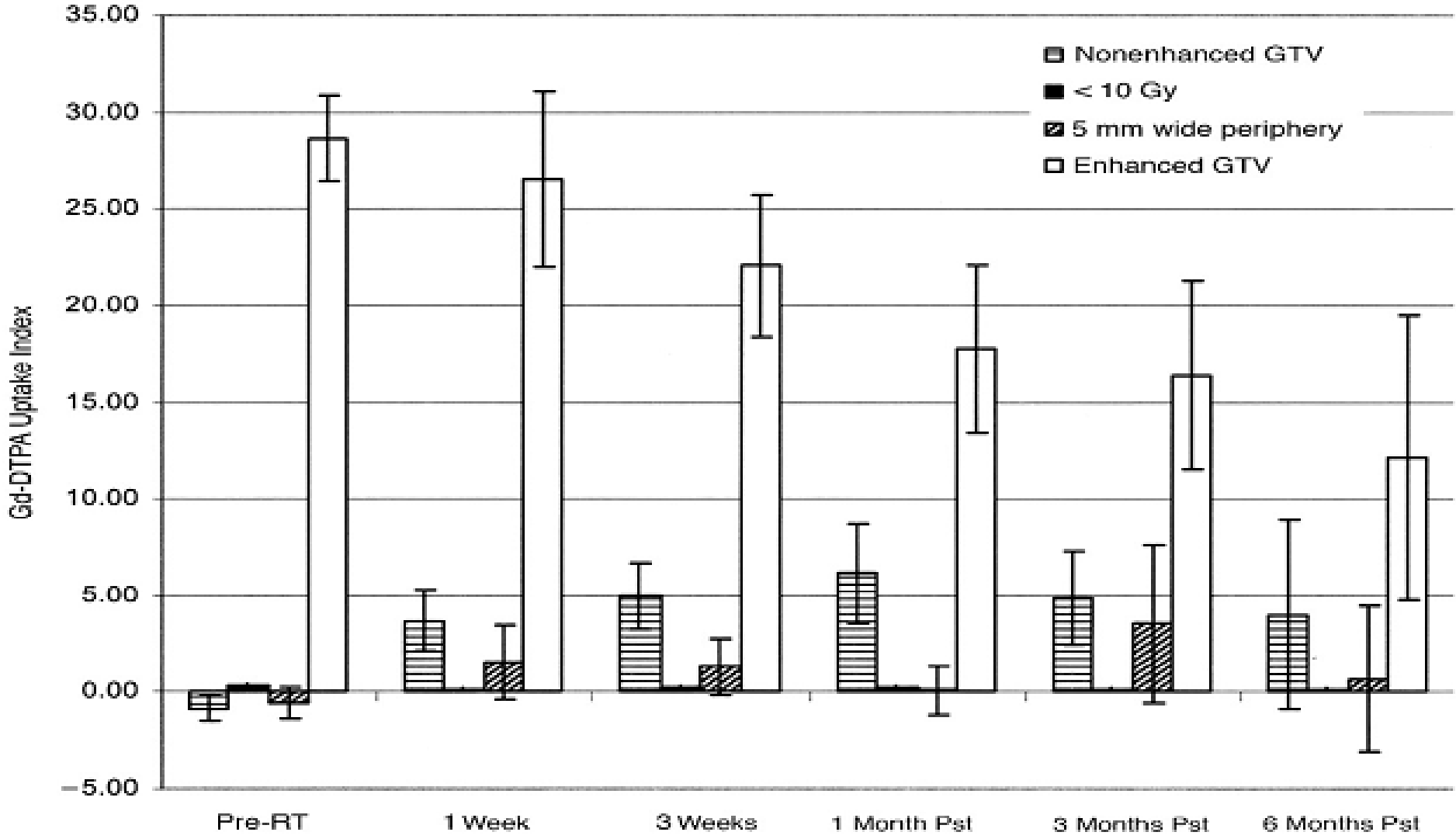

Copyright © American Society of Clinical Oncology

Cao, Y. et al. J Clin Oncol; 23:4127-4136 2005

Conclusions

- Conformal RT may selectively increase BTB compared to BBB

- Optimal time window for drug delivery occurs 3 weeks following RT to one month after completion of treatment

Water Diffusion Values Change During Treatment

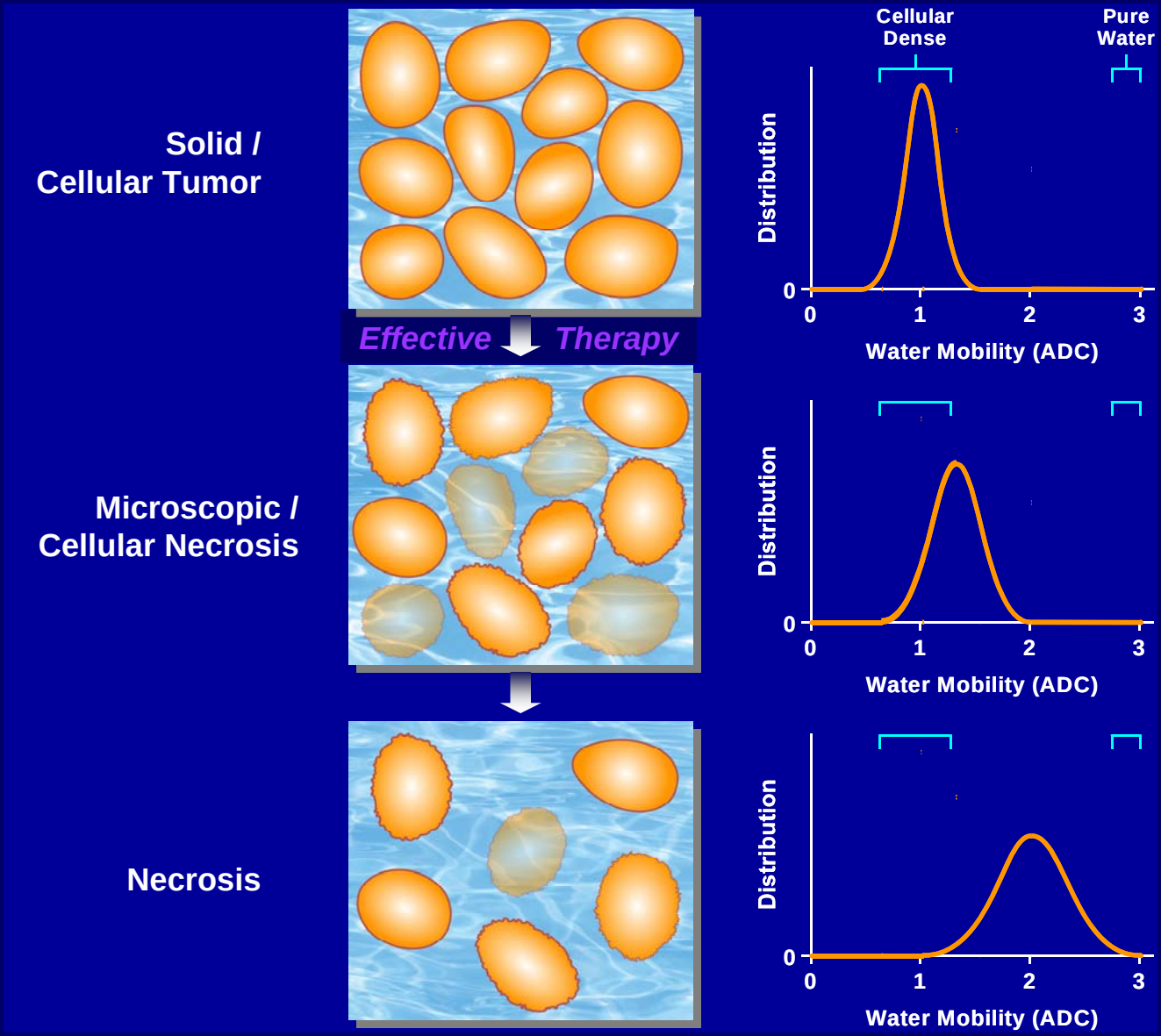

Validation of PRM_{ADC} in a Glioma Model

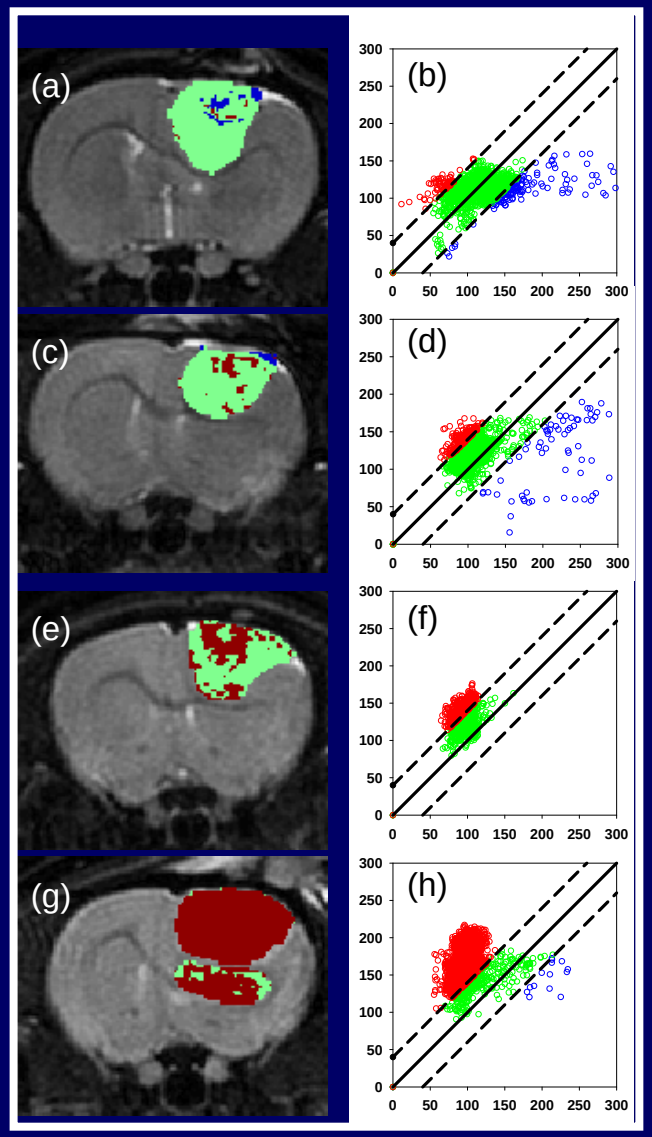

PRM_{ADC} measured at 4 days post-tx correlates with outcome/survival

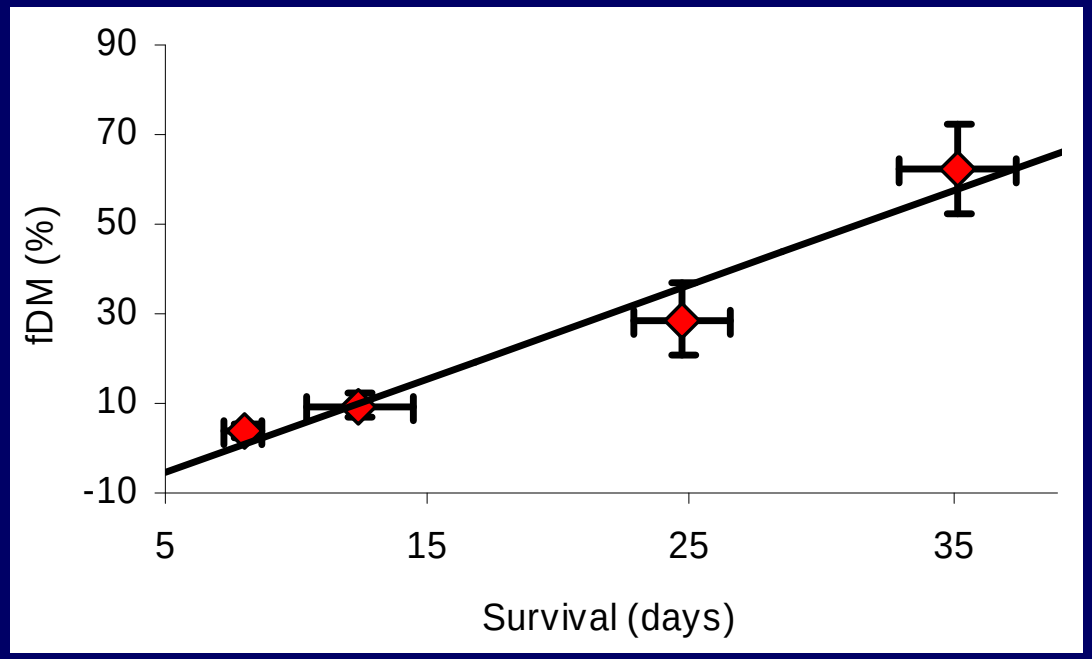

To validate an early imaging biomarker of cancer treatment response, correlation with an outcome measure (i.e. survival) was done.

Neoplasia, 8, 259-67, 2006

PRM Analysis As Potential Early Predictor of Response in GBM

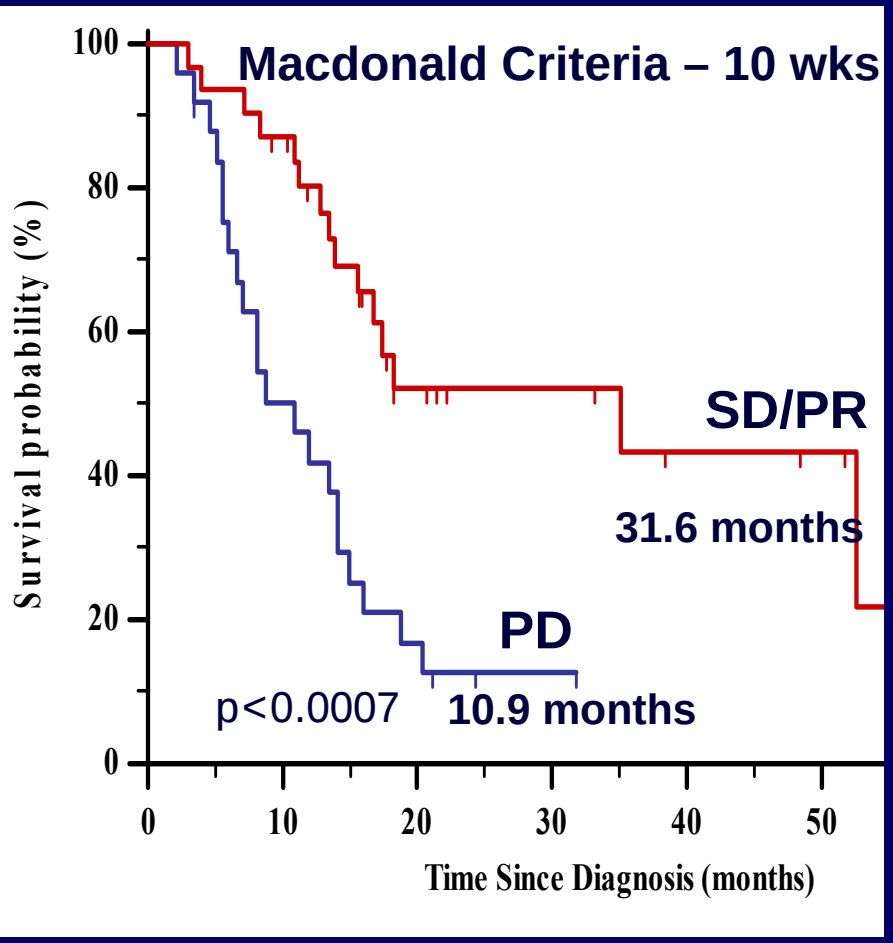

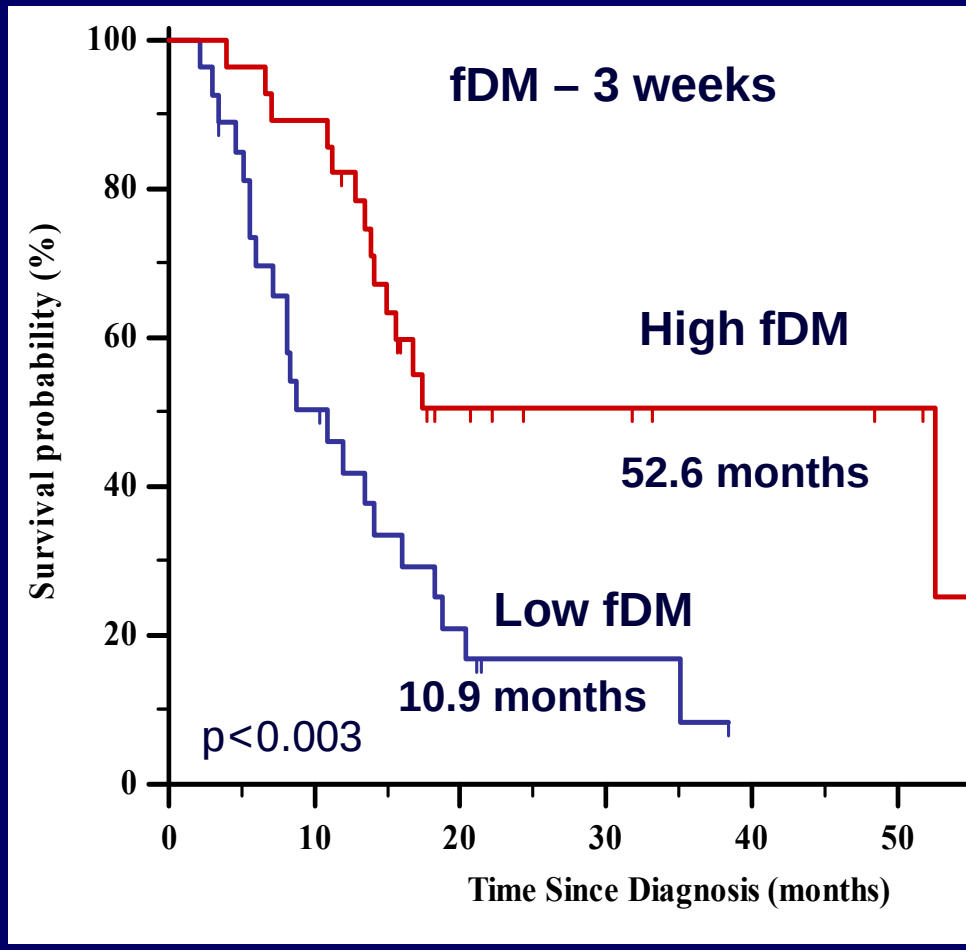

Hamstra et al, JCO 2008

Overall Survival as a Function of PRM_{rCBV} at 3 Weeks

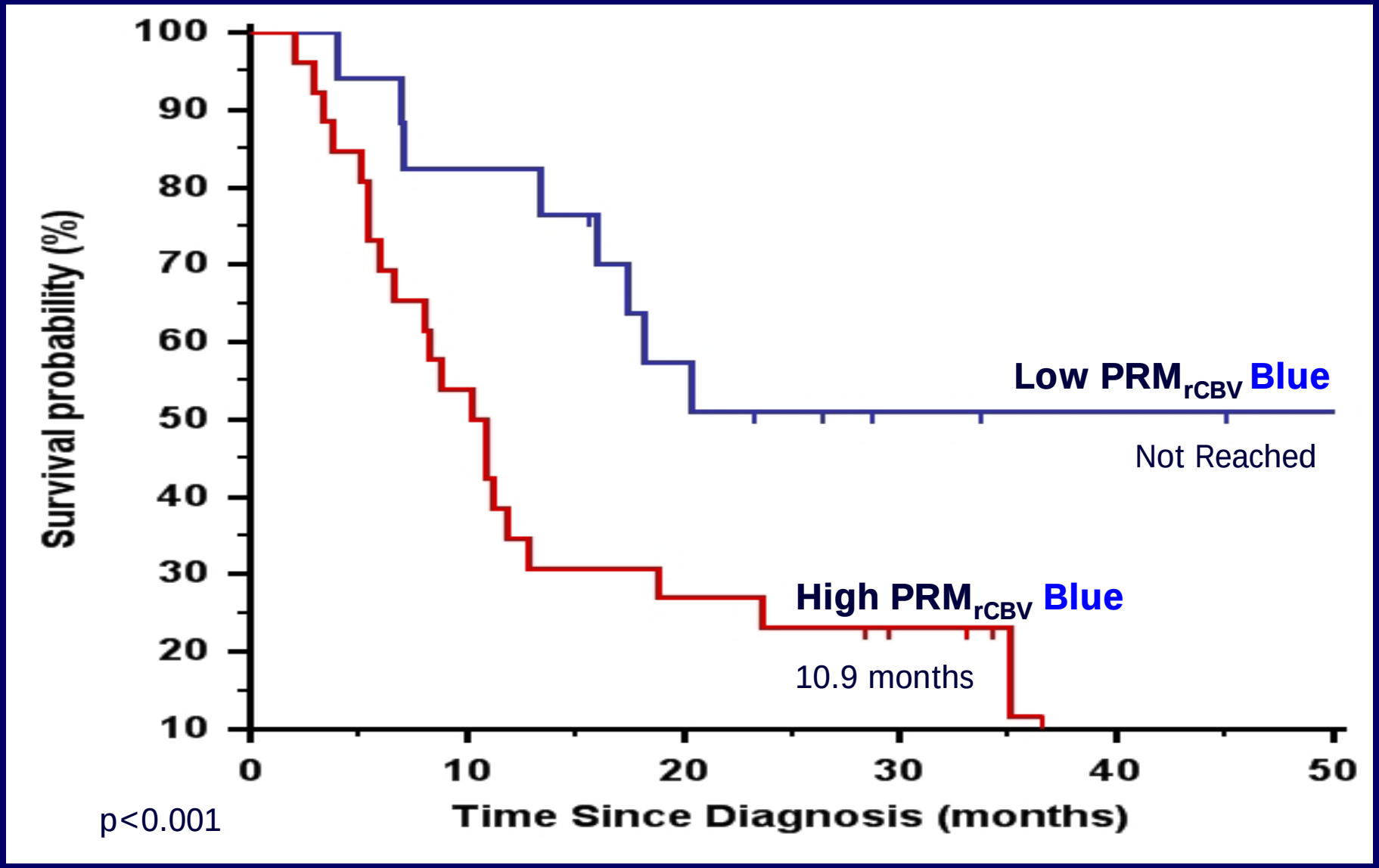

Summary

- Changes in diffusion (PRM_{ADC}) and perfusion (PRM_{rCBV}) were both early predictors of survival

- Combination of PRMs provided a more powerful early predictor of response than either alone

- PRM analysis may improve assessment of tumor response and allow for adaptive therapy

Neuro-Cognitive Decline Following Whole Brain RT

- Several studies have demonstrated improvement in local control as well as decreased distant failure in brain metastases with whole brain RT

- Concern for neuro-cognitive dysfunction associated with WB RT

MD Anderson Randomized Trial Schema

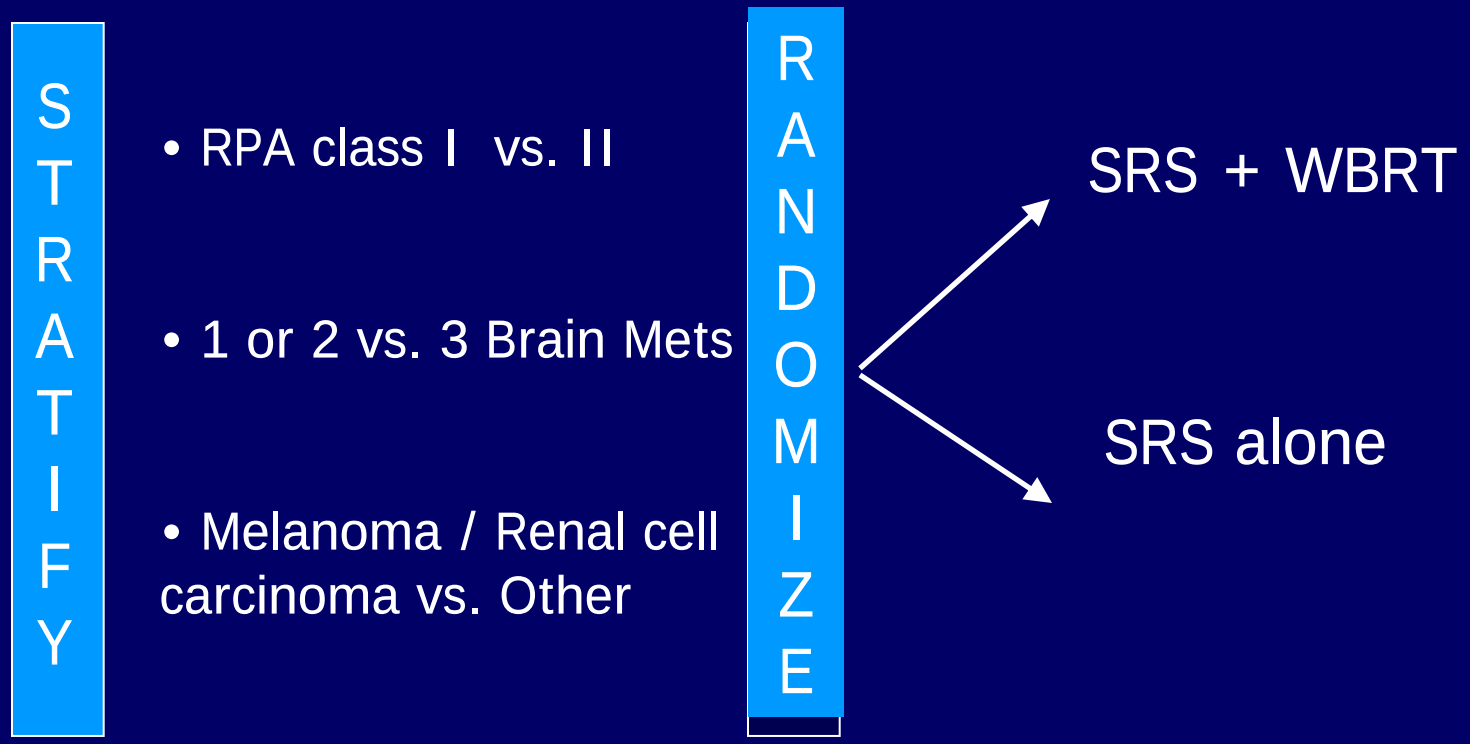

Courtesy of Eric Chang, Plenary ASTRO 2008

Neuro-cognitive Decline 4 months post RT
HVLT Immediate Recall

	Mean Probability of NCF Decline
SRS	**23%**
SRS+WBRT	**49%**

96% conf

Courtesy of Eric Chang, Plenary ASTRO 2008

Neuro-cognitive decline correlates with tumor growth

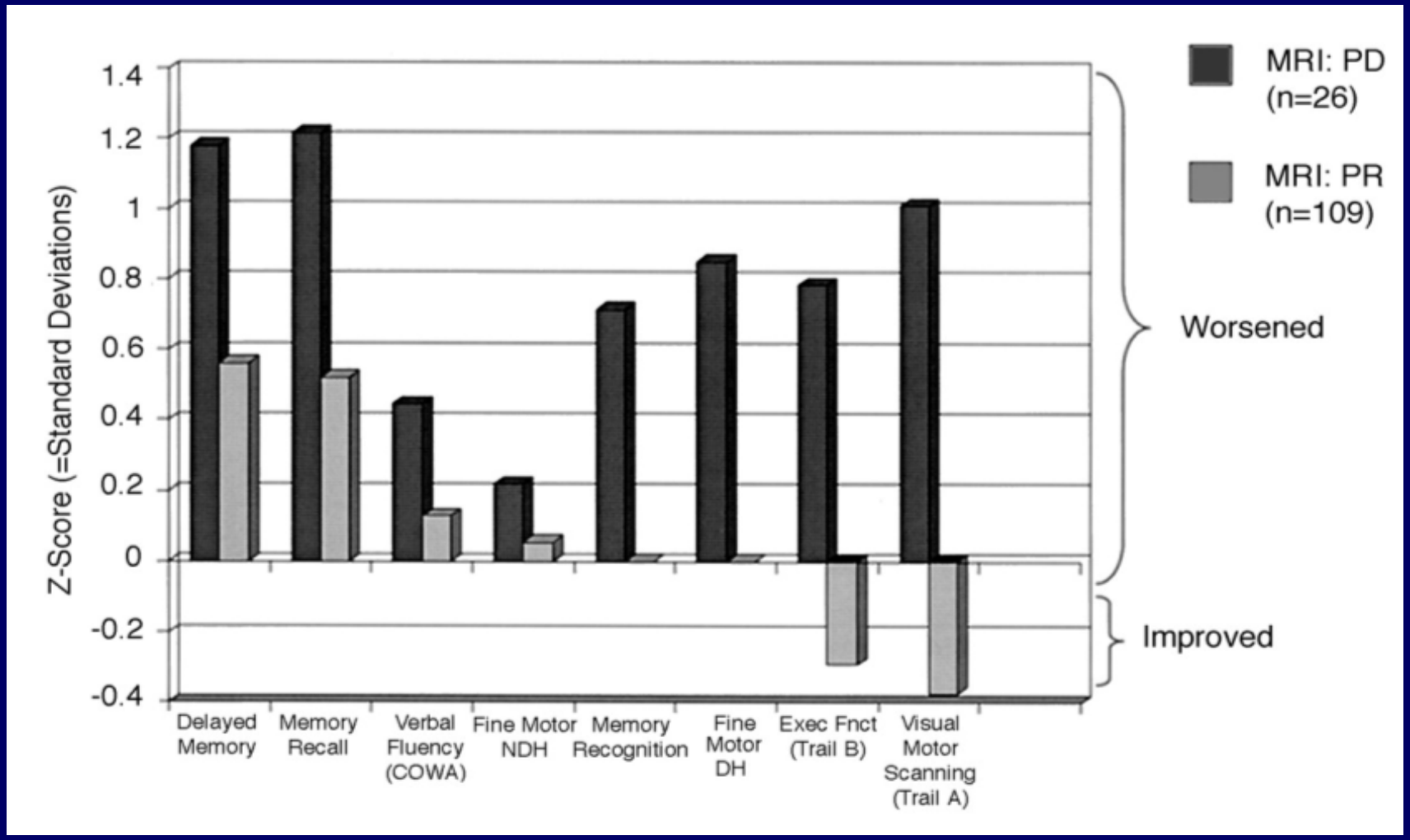

Meyers, C. A. et al. J Clin Oncol; 22:157-165 2004

Brain Metastases Control

	1 yr Local Brain FFP	1 yr Distant Brain FFP
SRS	67%	45%
SRS+WBRT	100% P=0.01	73% P=0.02

Chang E, ASTRO 2008

Introduction

- To develop early imaging biomarkers predictive of response and late sequelae

- To develop therapeutic strategies in preventing CNS toxicity

MR Diffusion Tensor Imaging

- Versatility of DTI
  - Assess individual fibers
  - Latency in axonal degradation
- DT indices
  - Potential imaging biomarker to assess for NAWM injury

Water Diffusivity in White Matter Fibers

University of Michigan Medical School

Normal Myelin Fibers

$\lambda_{\parallel} >> \lambda_{\perp}$

Demyelinated Fibers

$\lambda_{\parallel} > \lambda_{\perp}$

$\uparrow \lambda_{\perp}$

Demyelination +Axonal Degeneration

$\lambda_{\parallel} \approx \lambda_{\perp}$

$\uparrow \lambda_{\parallel}$ & $\uparrow \lambda_{\perp}$

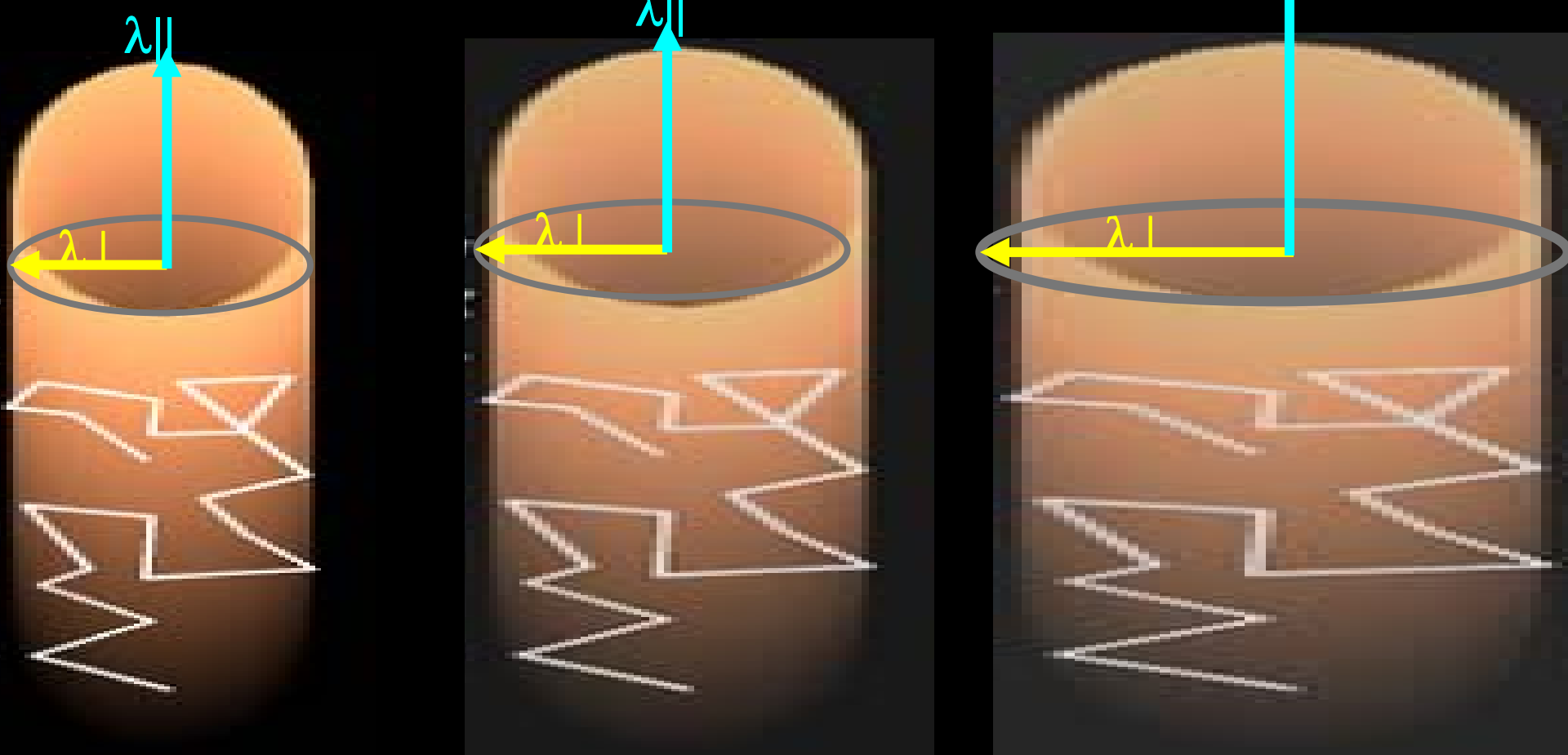

University of Michigan Medical School

Hypothesis

- Radiation may lead to demyelination and structural degradation of NAWM
- Extent of demyelination and axonal injury may be dose-dependent
- Seen prior to development of neuro-cognitive deficits or MR imaging changes

Prospective DTI Studies in LGG

Diffusion Tensor Imaging (Structural Integrity)

- Pre RT
- During RT: Week 3 and 6
- Post RT: Week 10 and 18

Neuro-cognitive Tests

- Trail Making A and B (executive function)
- Hopkins Verbal Learning (memory)
- Controlled Word Association (verbal fluency)
- Pre-RT
- Post-RT: Week 10, 32, 78

Fractional Anisotropy in Normal-Appearing White Matter

FA = 0.52

Pre-RT

FA = 0.37

10 Wk RT

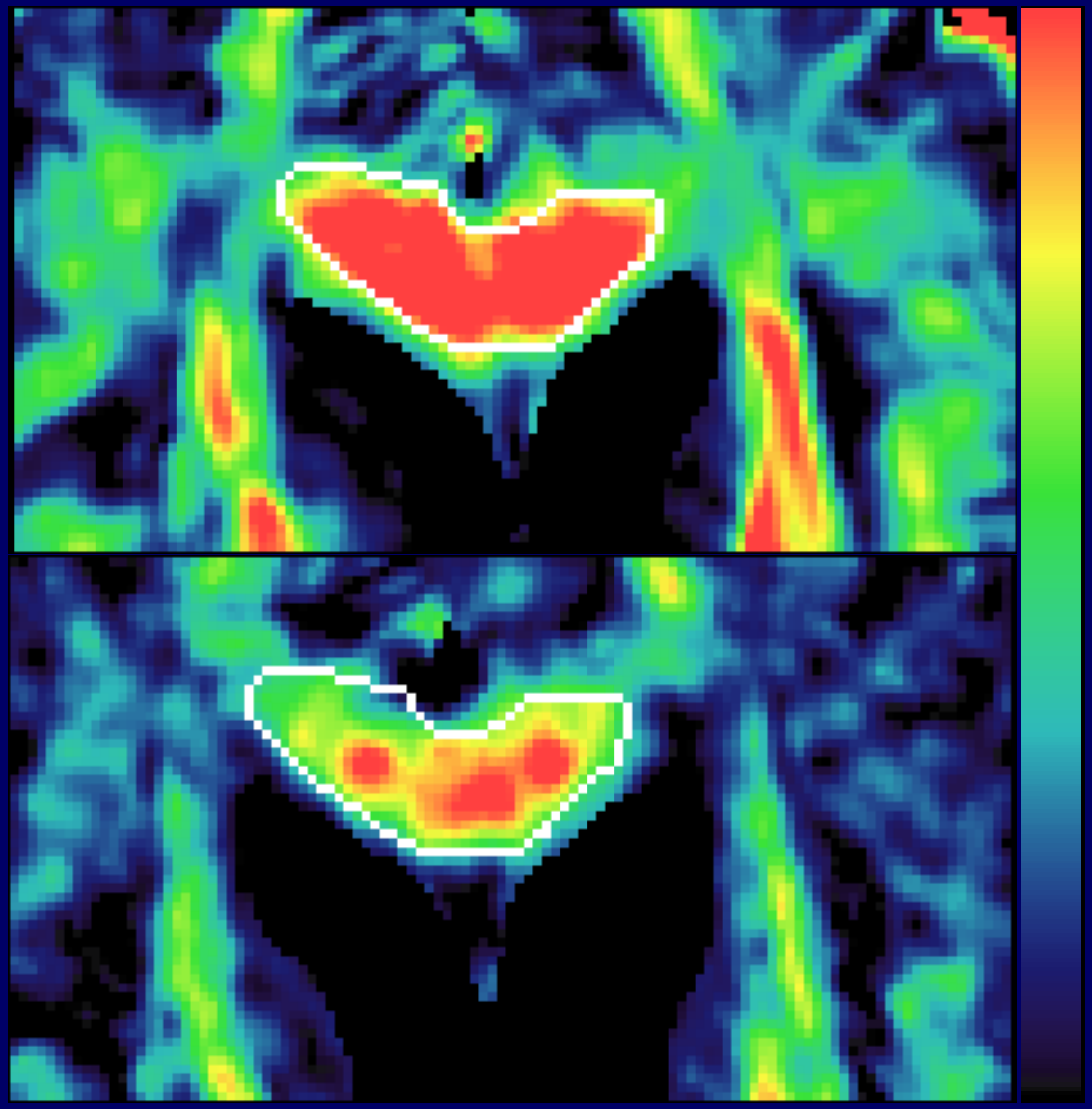

Temporal Changes in Fractional Anisotropy of Normal Tissue

Pre RT (week 0) During RT (week 3) Post RT (week 18)

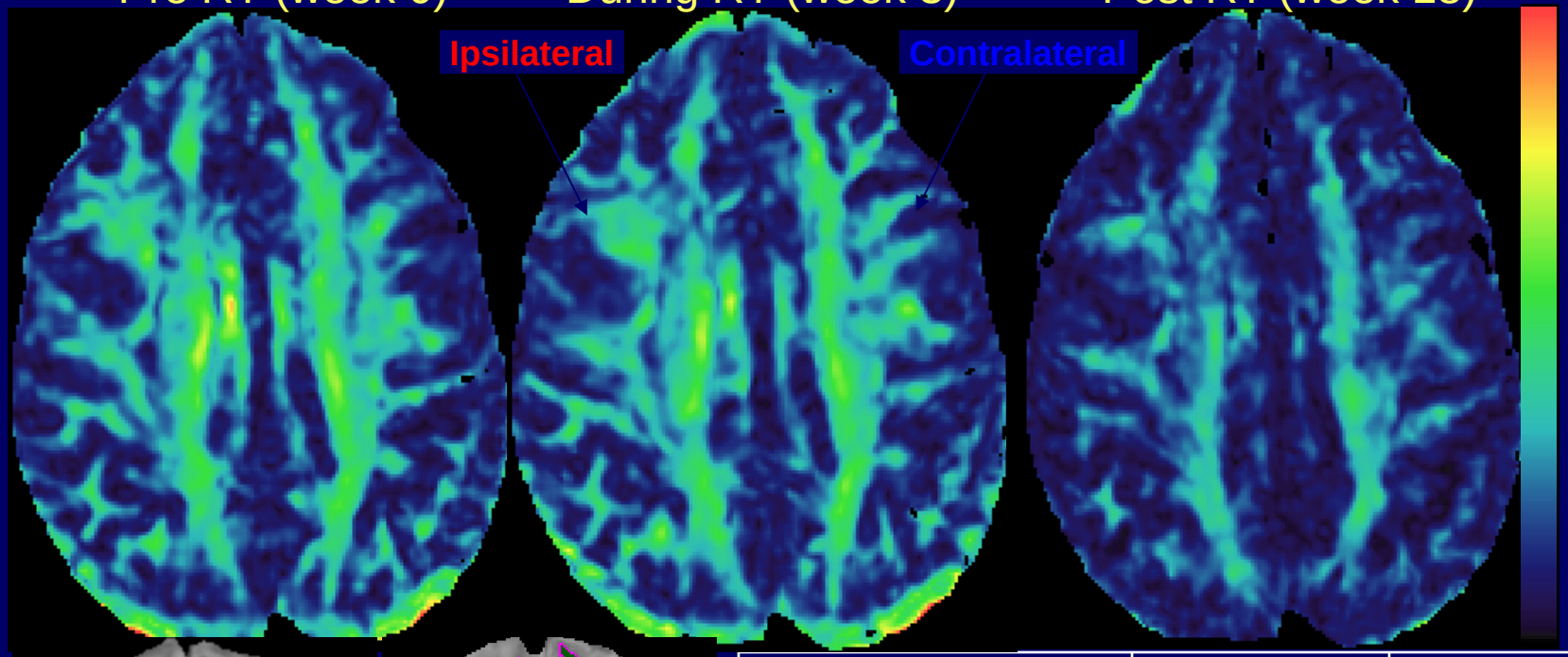

T2 Image

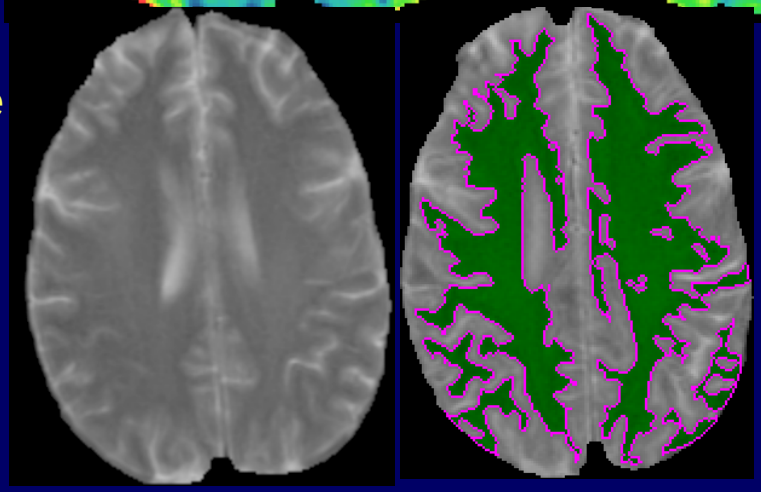

Region	*3 weeks*	*18 weeks*
Ipsilateral	-3%	-33%
Contralateral	<1%	-26%

RT Dose Effects of Hippocampus

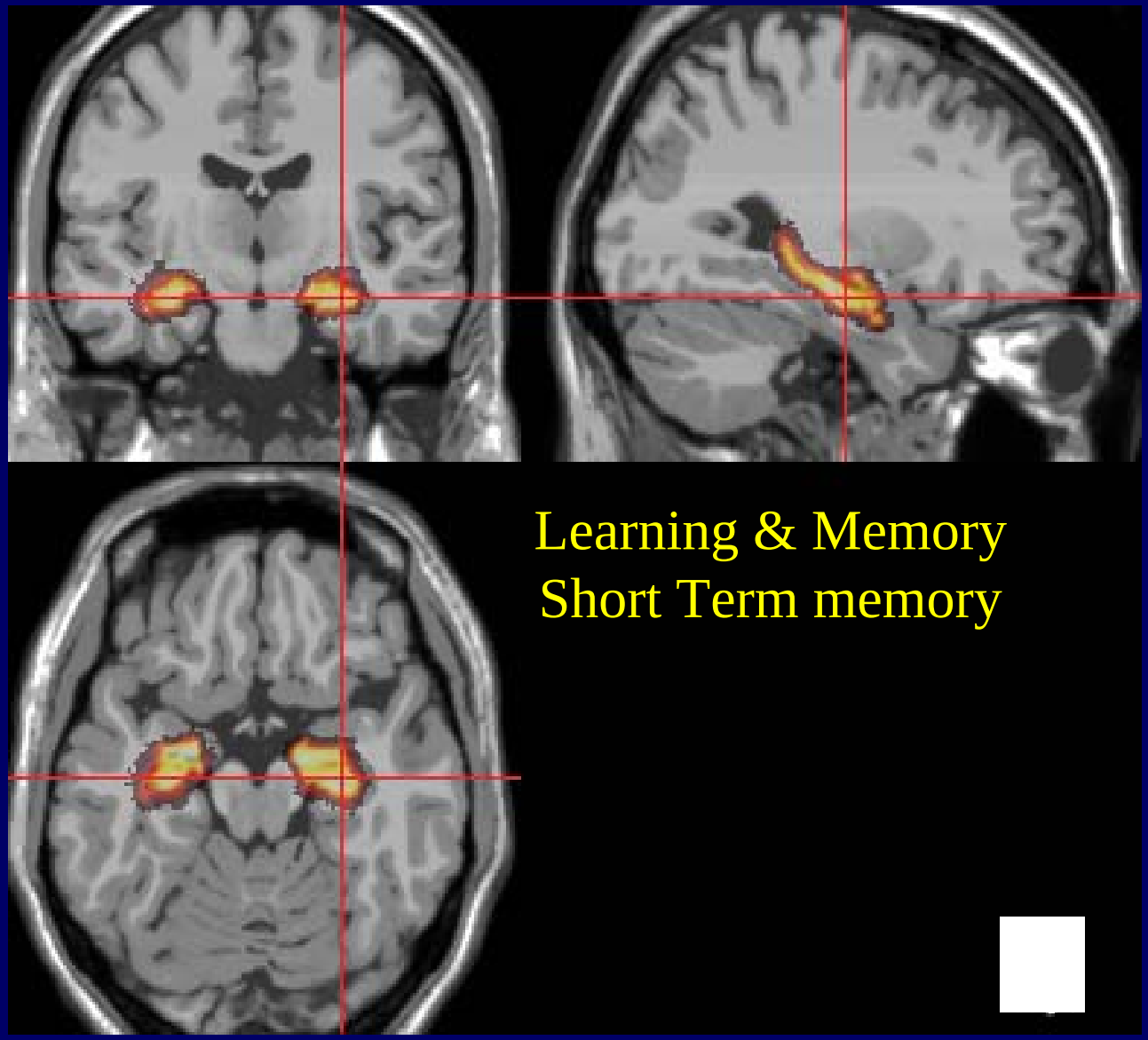

Diffusion Tensor Imaging

Detect early changes in structural degradation of para-hippocampus

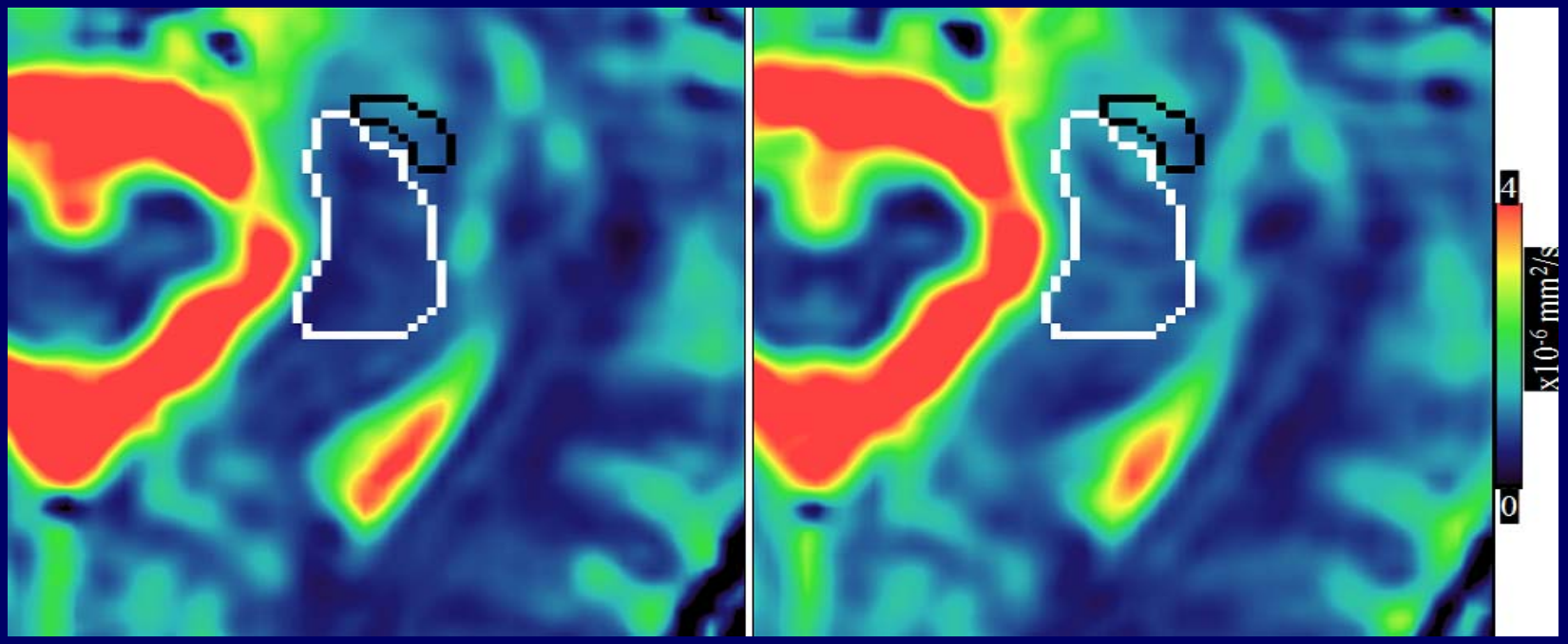

PRE-RT

Wk3 During RT

V. Nagesh, ASTRO 2008

Early DTI Changes in Hippocampus associated with neuro-cognitive decline

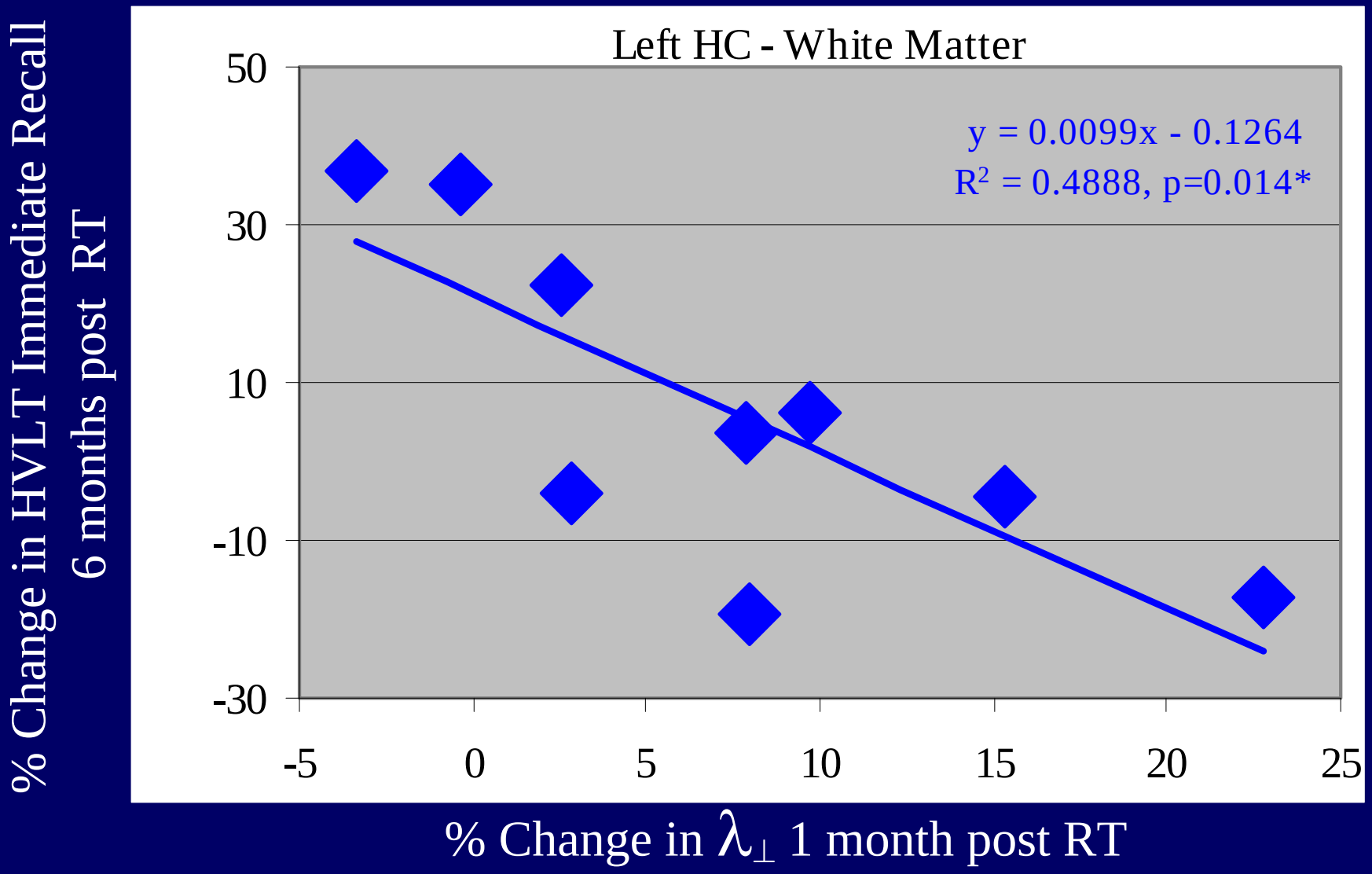

Conclusions

- Progressive temporal decline in cytoarchitecture
- DTI Indices able to detect early changes in micro-structural integrity
- Dose-dependent degradation of normal tissue
- Early changes in structural properties of normal tissue may relate to delayed neurocognitive decline

Vascular Changes Following RT

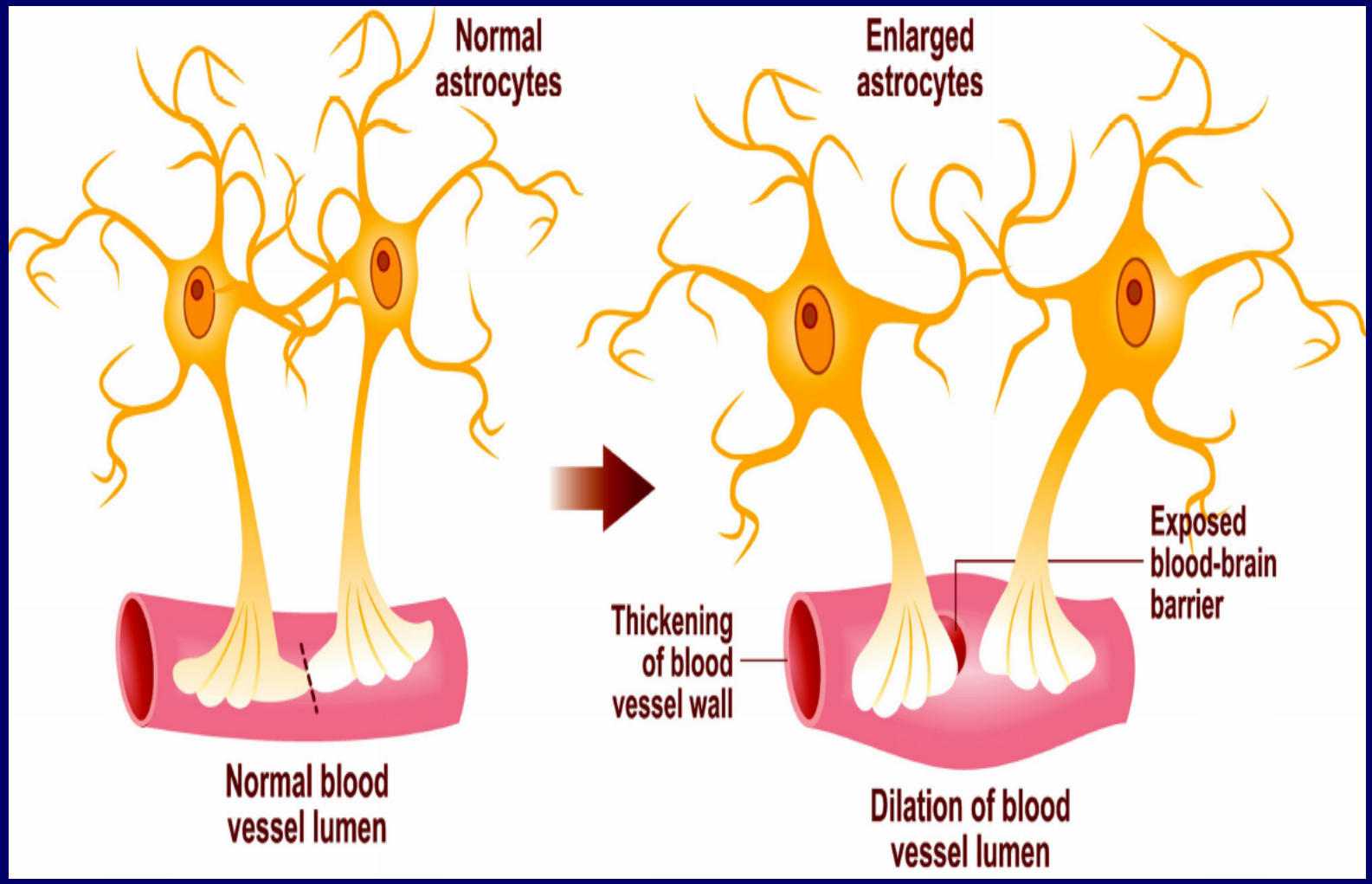

Temporal Changes in K trans

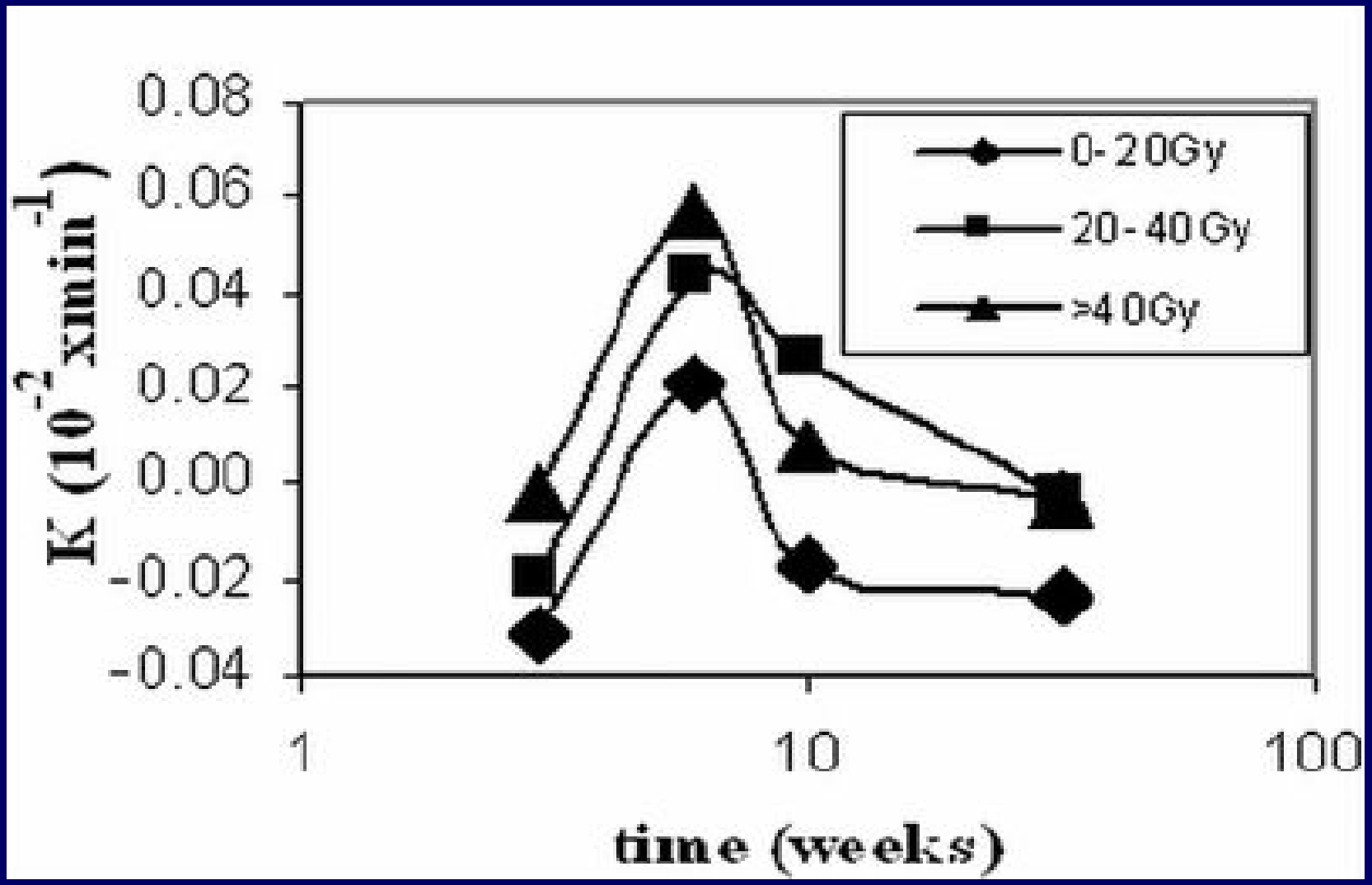

Vascular Permeability Associated with Neuro-Cognitive Decline in LGG

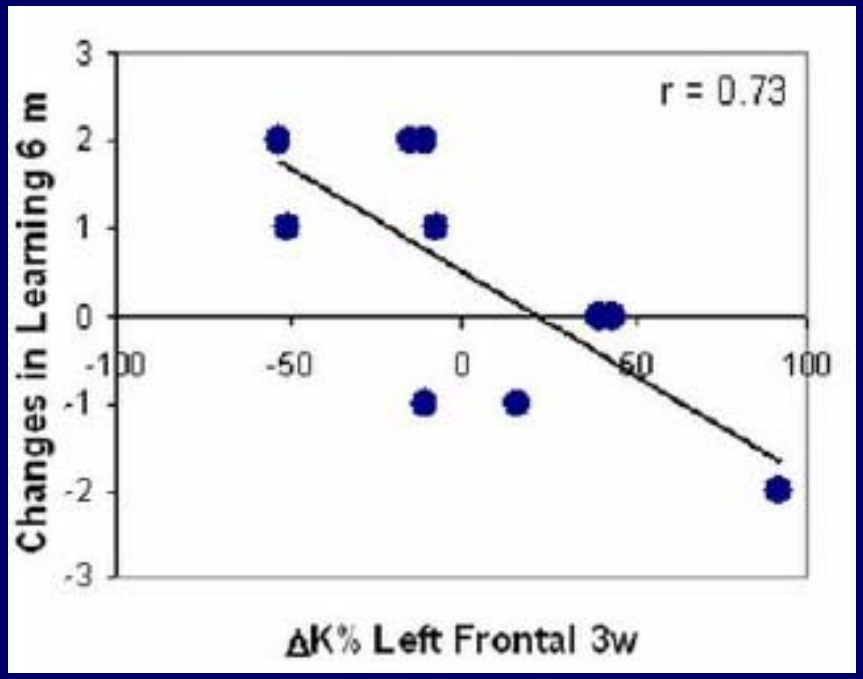

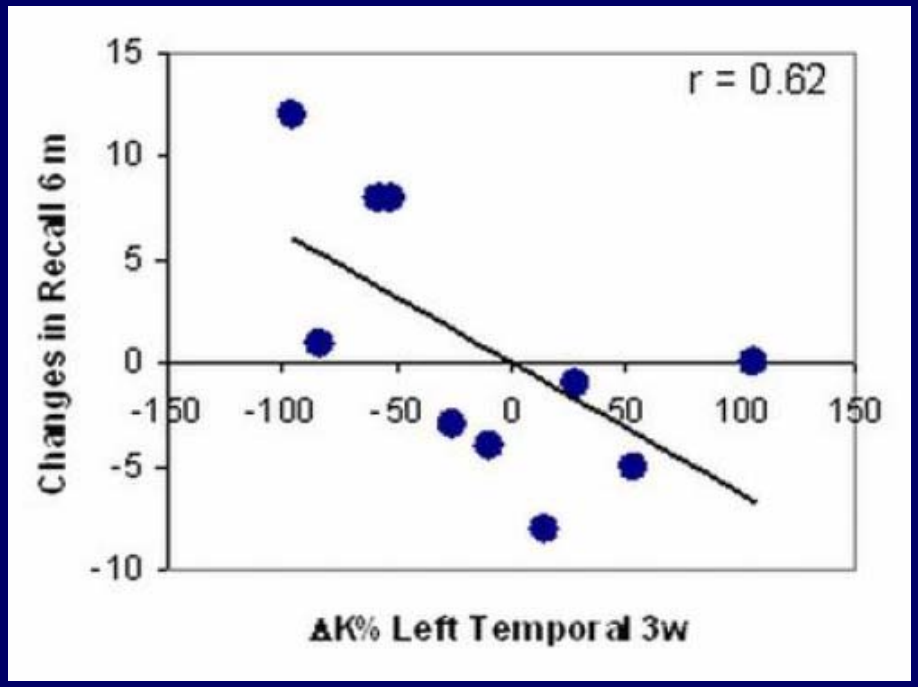

Schema

Clinical Evaluation MRI/PET scans Neuro-psych Eval	Whole Brain RT 24-30 Gy	Clinical Evaluation MRI/PET scans Neuro-psych Eval
Pre-Tx		6 and 12 mos. Post-RT

DTBZ Imaging Pre and Post Prophylactic Cranial RT

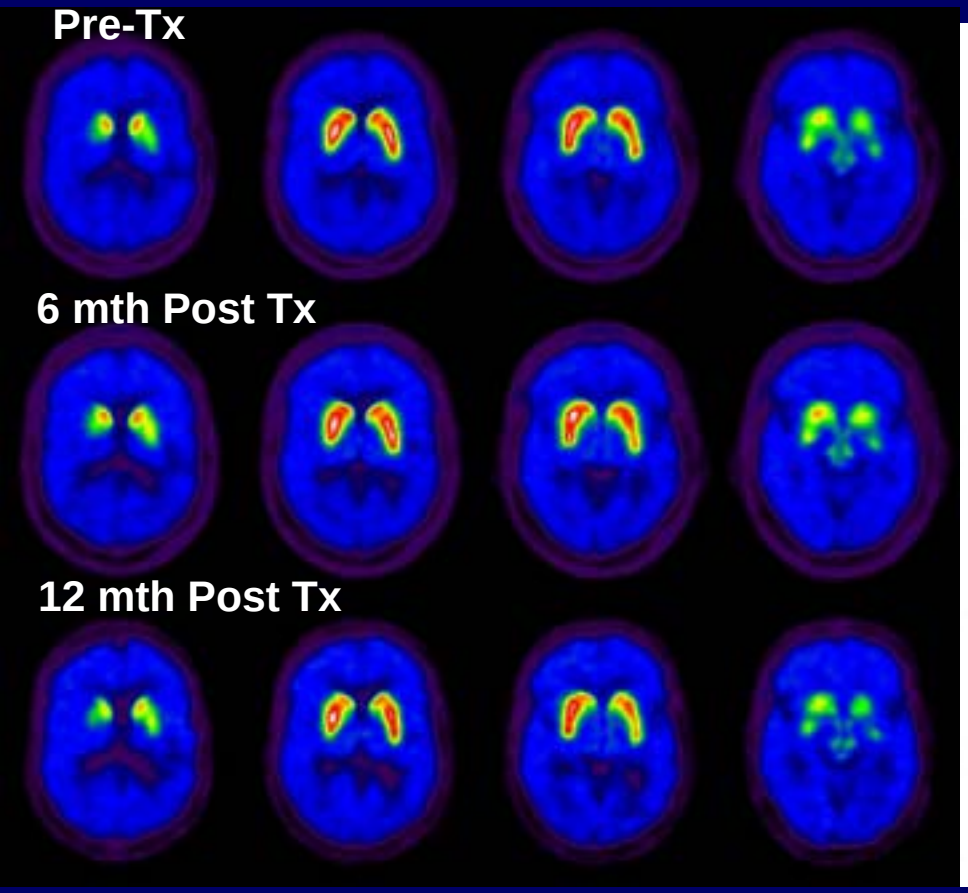

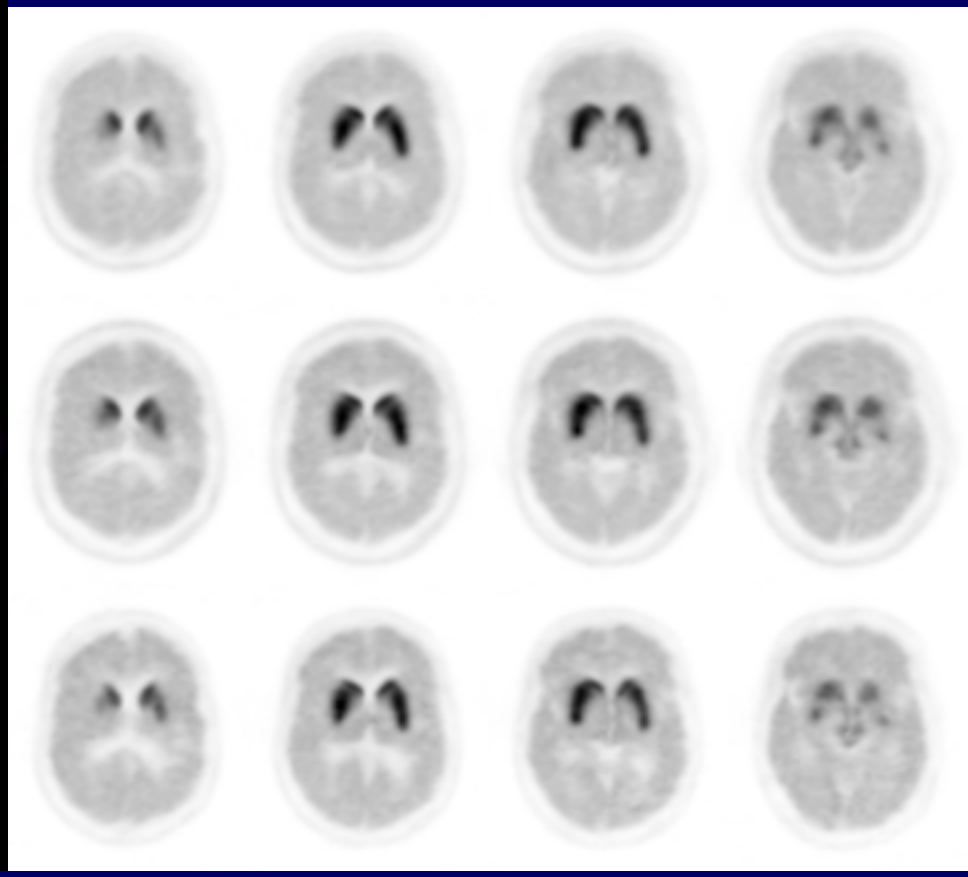

11C-Flumazenil PET Imaging Pre and Post-Prophylactic Cranial RT

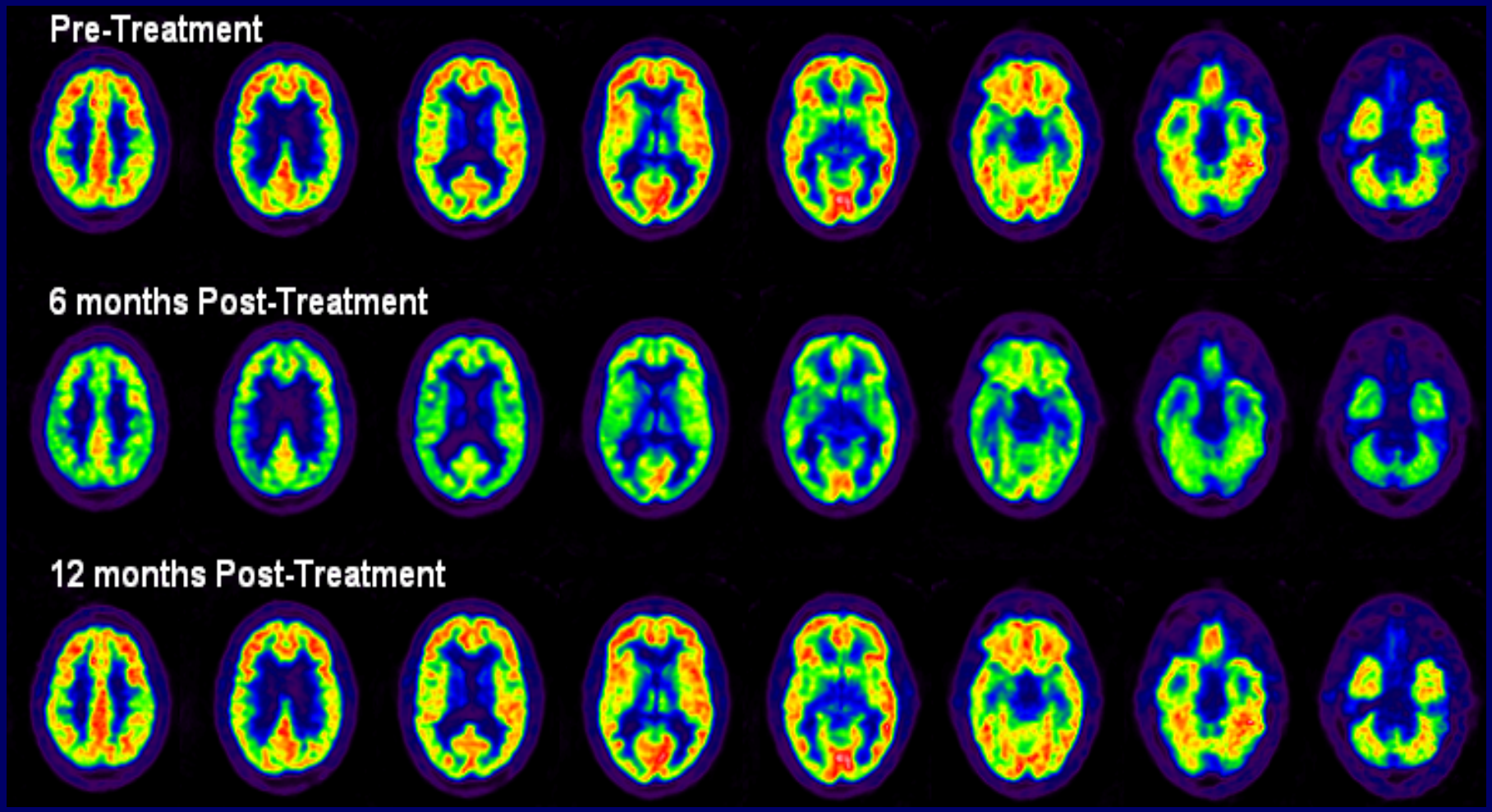

University of Michigan Medical School

Acknowledgements

- Vijaya Nagesh, Ph.D
- Yue Cao, Ph.D
- Kirk Frey, M.D, Ph.D
- Bob Koeppe, Ph.D
- Thomas L Chenevert, Ph.D
- Theodore Lawrence, M.D, Ph.D
- Larry Junck, M.D